
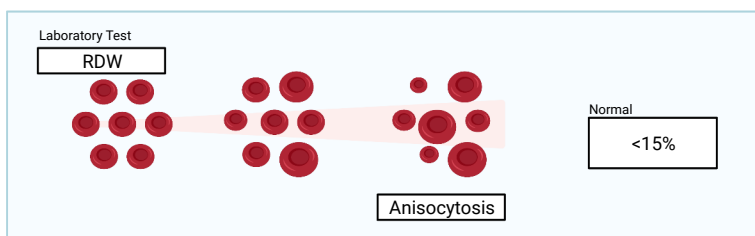
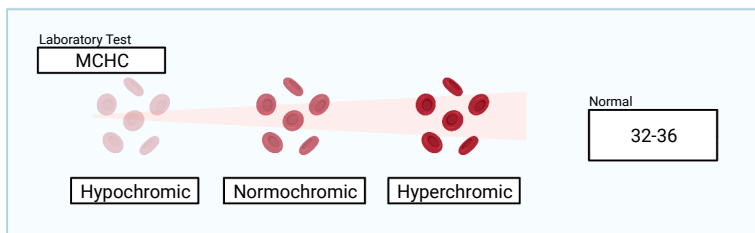
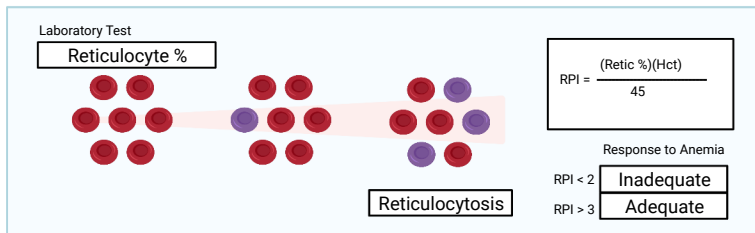
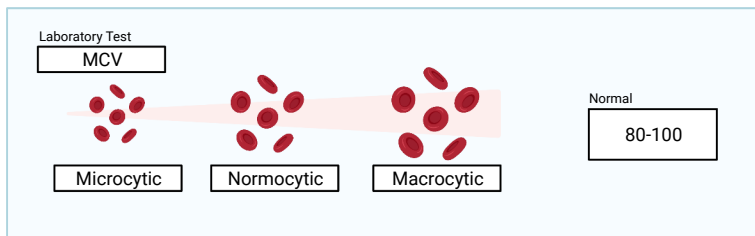



RBC/Plt Indices



Pronormoblast



Basophilic Normoblast



Polychromophilic Normoblast



Orthochromatic Normoblast



Polychromatic Erythrocyte

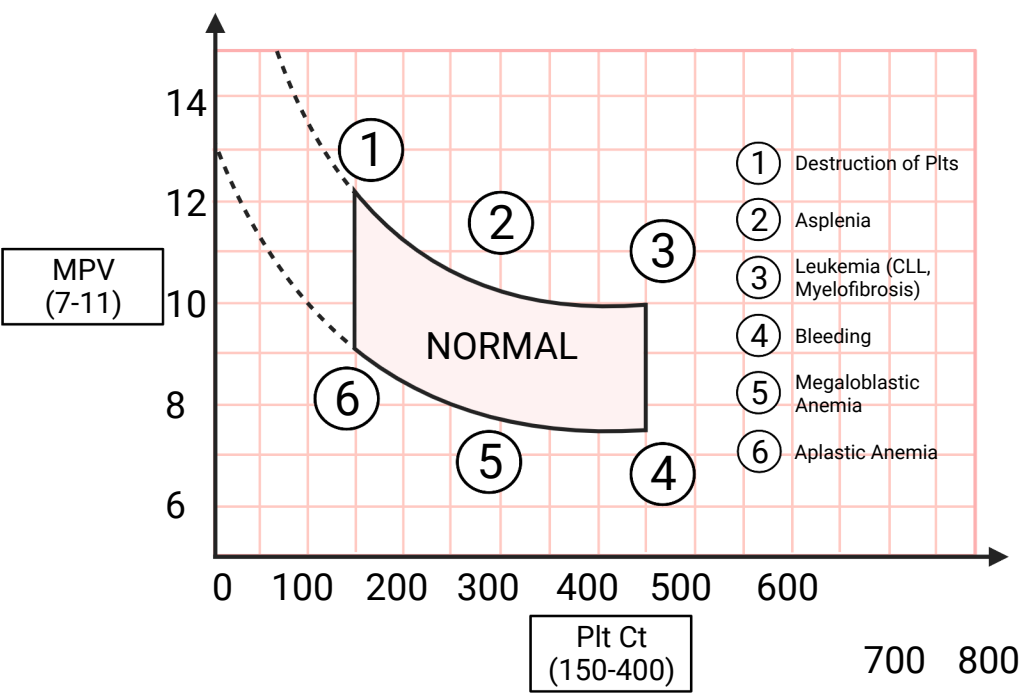


Erythrocyte

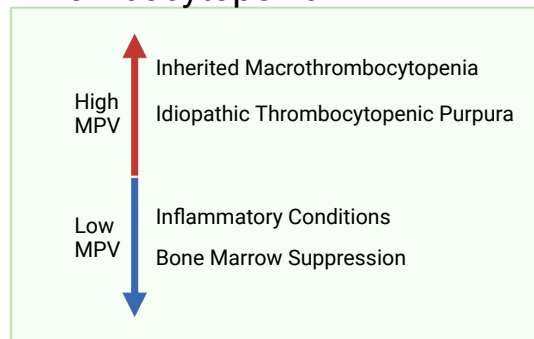
Can be Seen in Newborns

↑ RBC Prod

Normal



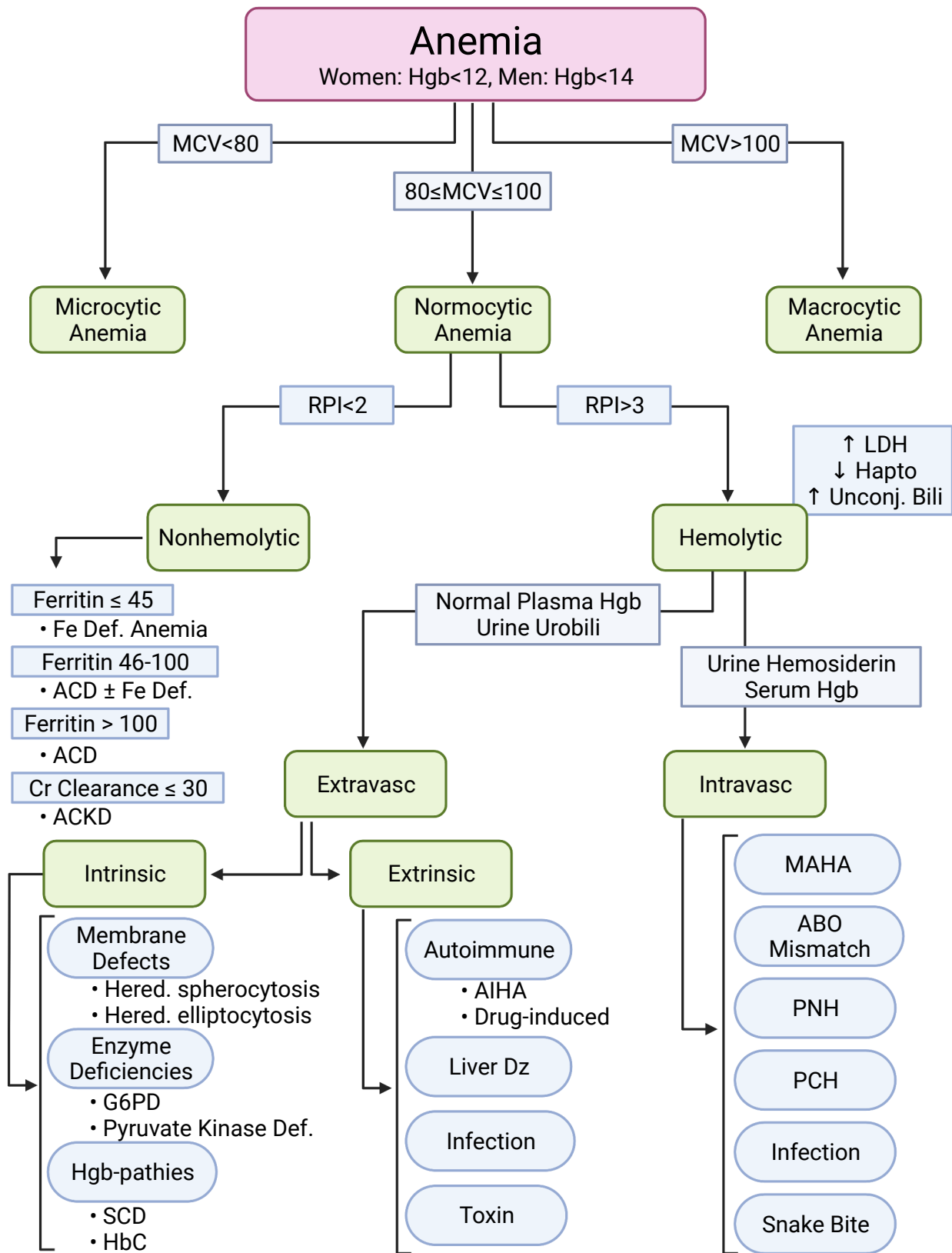
Thrombocytopenia



MPV Associations

- High MPV
 - ↑ MI Risk
 - ↑ MI/Stroke Mortality
 - Seen in Hypothyroidism & HTN
 - Recurrence of APS Thrombosis
 - Vitamin D Deficiency
 - Poor Prognosis in Cancer
- Low MPV
 - Chemotherapy
 - Seen in IBS
 - Seen in Women with HIV

Cullen Lilly



Cullen-Litkey

Iron Absorption, Transport, and Storage

